

EMPYEMA
&
EMPYEMA NECESSITANS

WHAT IS PAST IS PROLOGUE

- Empyema first described by Hippocrates in 500 B.C – o.d was the only method .
- First time in 20th century(1917) closed drainage was adopted .
- Intrapleural fibrinolytic therapy in 1949.

DEFINITION

- EMPYEMA ; PUS IN THE THE PLEURAL CAVITY

definition

- Empyema necessitans is a spontaneous discharge of an empyema that has burrowed through the parietal pleura, usually into the chest wall, to form a subcutaneous abscess that eventually may rupture through skin.

histology

Normal pleural histology [five layers]

Mesothelial

Loose connective tissue

External elastic lamina

Interstitial zone

Internal elastic lamina

**Mature fatty tissue is the landmark for
identification of parietal pleura**

CLASSIFICATION

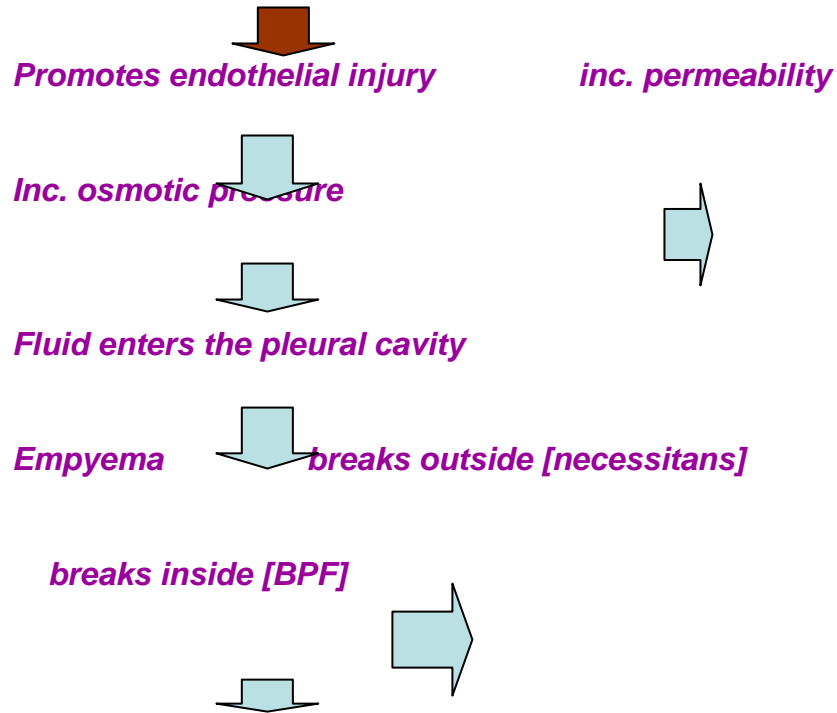
- Secondary empyema :
more common secondary to pneumonia (synpneumonic effusion)
 - Primary empyema :
empyema without pneumonia (most commonly tubercular) .
- Iatrogenic empyema

pathology

Organisms migrate into the pleural cavity- direct ext/contiguous route
Contiguous infection {synpneumonic infection}

Increased polymorphs {from the lung these migrate into the pleura}

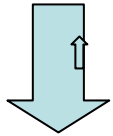
Releases inflammatory cellular components and toxic oxygen species



Pathology

direct extension

- Pleural effusion [mostly tubercular]



- Tapped



- Infection introduced



- empyema

Stages of empyema

[Natural history]

1. Exudative: fluid is sterile in contiguous and **infected in direct cont.** [glucose>60,pH>7.2,LDH<500]
2. fibrinopurulent: bacterial multiplication inc. polymorphs, deposition of fibrin on both pleural surfaces [glucose<40,pH <7.2,LDH>1000]
3. Organization stage: loculations, inelastic membranous peel, trapped lung

Pathphysiology

- PERFUSION IS AFFECTED MORE THAN VENTILATION

RADIOLOGICAL FINDINGS

- CXR mpyema w.out BPF

PA view: obliteration of costophrenic angle [75 -500 ml]

Lateral view: more sensitive

Decubitus view: subpulmonic

can detect upto 5 ml

Cxr

empyema with BPF

- The air fluid level interface extends completely from the mediastinum to the chest wall in PA view .
- The air fluid interface is continuous from the anterior to the posterior chest on a lateral view.
- The air fluid level interface extends across the fissure.
- Mediastinum is pushed to the other side .

Cxr of loculated empyema

- Lies near the chest wall .
- Makes an obtuse angle with the parenchyma .
- Homogenous shadow can cross the fissure .

CT FINDINGS

- **1.without BPF**
 - **Split pleura**
 - **Underlying lung compression**
 - **Density of the fluid**
 - **Location near the chest wall**
 - **Makes an obtuse angle**
 - **Lenticular shape**
- **2.With BPF**
 - **Air fluid level**
 - **Cavity wall is smooth compared to irregular in abscess**

Loculated empyema with BPF VS intraparenchymal lesion(cavity / bulla with fluid, lung abscess)

- Air fluid level does not cross the fissure .
- In PA and lateral view the length of air fluid interface is equal .
- Mediastinum is pulled or is in centre .
- Change in position does not change the air fluid level as much as in loculated empyema.
- There is compression of the bronchi and pulmonary vessels as compared to the cut off sign seen in loculated empyema and intraparenchymal lesion respectively.
- An attempt to aspirate fluid generally fails/ free fluid not aspirated in intraparenchymal lesion as compared to loculated empyema

MR IMAGING

- Useful in differentiating lung abscess and empyema with BPF AND ALSO small empyema and pleural thickening.
- T 1 W images- low signal intensity
- T 2 W images – increased intensity of pleura but not within the parenchyma

- Note: the only two other indications of MRI chest are mediastinal lymphadenopathy and mediastinal ext. of Ca

Ultrasonography

1. USG shows limiting membranes suggesting the presence of loculated collections even when they are invisible by CT scan .
2. lung abscess.
3. hydropneumothorax.
4. Transudates are usually anechoic, whereas exudates can be echoic or anechoic.
5. Sonography can distinguish solid from liquid pleural abnormalities [pleural thickening]
6. Quantification of fluid and marking the most dependent site.
7. localizing a communication b/w the pleural cavity and empyema necessitans

Principals of treatment

- Pleural fluid should be sampled for diagnostic purposes.
- All effusions should be imaged .
- The aim should be to drain the fluid either surgically or conservatively depending upon the stage /category of effusion .
- In all effusions antibiotics should be used .
- nutrition should be maintained .

- **CATEGORIZATION OF EFFUSIONS
(ATS guidelines) .**

- **STAGING OF EFFUSIONS(BTS
guidelines)**

TREATMENT MODALITIES OFFERED

- Observation .
- Recurrent thoracocentesis .
- Intercostal drainage .
- Intercostal drainage with fibrinolytics .
- Intercostal drainage followed by thoracoscopy and adhesionolysis / surgery .
- Surgery alone .
- Intercostal drainage followed by open drainage .

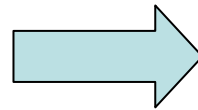
Antibiotics

- All patients should be given antibiotics.
- Always to be guided by c/s .
- Where culture is sterile antibiotics should be governed by principles of treatment of CAP .
- Treatment of nosocomial infection should be guided by c/s .
- Aerobes [gm +ve ,gm _ve] and anaerobes should be covered .
- For gm _ve bacteria aminoglycosides are ineffective as they do not act in acidic medium .

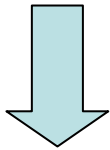
Intercostal drainage

INDICATIONS

- Frankly purulent .
- Ph < 7.2 ,gm stn +ve
culture +ve
- Very large/loc. Eff.



ATS cat 3&4



BTS complicated
parapneumonic eff. ,
empyema

INTERCOSTAL DRAIN

1. Position: usg marked most dependent position/safe triangle.
2. Size
3. Technique : seldinger/mallikott
4. In case within 24 hrs patient does not improve then the reason should be found
 - a . improper positioning
 - b. wrong antibiotics
 - C . fibrinous cast over the visceral pleura.

Intrapleural fibrinolytics

- These are used in complicated parapneumonic eff. /cat 3 patients wherein pus is not formed but the effusion is either loculated or has septae .
- These have no role after pus formation

Agents and doses

- Streptokinase : 2.5 million units o.d x 6
- Urokinase : 1 million units o.d x 6 days
- tPA: 10 mg o.d x 6 days
- DNAase : undertrial

thoracoscopy

- To break adhesions
- To VISUALISE THE pleura .

Intercostal drainage with fibrinolytics with or without pleuroscopy is dependant upon the septae formation ,usually up to two ICD tubes are put in the major loculi ,otherwise, pleuroscopy and breaking of the septae may be done

**OBSERVATION
ONLY FOR CATEGORY 1**

Recurrent thoracocentesis

Exudative stage /simple parapneumonic
effusion/ cat. 2

Some cases of purulent stage

Open drainage

- Prerequisites

- 1 . The parietal and visceral pleura have become adherent.
2. the pleura is fixed such that it does not collapse due to atmospheric pressure.

Open drainage ... methods

- PC WINDOW
- OPEN DRAINAGE TUBE

Decortication

Indications

1. organized /loculated empyema
with/ w out BPF

Idea of decortication is to release the trapped lung. It may be combined with lobectomy and muscle flap transposition.

FOOTNOTES ON EMPYEMA NECESSITANS

- An empyema necessitans may not point immediately over the underlying empyema . The pus may track along tissue planes [including intercostal vessels] and commonly points anteriorly. Radiological localization is necessary before embarking upon definite treatment
- In neglected cases pus may track backwards b/w the ribs and then down the paravertebral tissue planes to present as s/c lumbar abscess.
- Unless underlying pathology is determined drainage of superficial abscess may result in permanent sinus formation.
- An ICD tube should be put into the empyema cavity at a site other than the communication it makes with empyema necessitans.

CONCLUSIONS

1. Stage the empyema properly.
2. assess the location by all available radiological methods
3. depending upon the stage treat empyema at the earliest
4. the grey zone of treating an empyema with septae by decortication vs. pleuroscopic adhesionolysis is physician dependent
5. always consider a chest abscess as empyema necessitans unless proved otherwise stage the empyema properly
6. role of PFT is minimal in preoperative assessment as empyema hampers perfusion more than ventilation

Take home message

- Drain the empeyma at the earliest

All the best..